

## “The Perils Of Excess”: Wilson’s Disease ----A Copper Connection

Saryu Gupta<sup>1</sup>, Manoj Mathur<sup>2</sup>

<sup>1</sup> Assistant Professor, Department Of Radiodiagnosis And Imaging, Government Medical College And Rajindra Hospital, Patiala (Punjab) India

<sup>2</sup> Associate Professor, Department Of Radiodiagnosis And Imaging, Government Medical College And Rajindra Hospital, Patiala (Punjab) India

---

**Abstract:** Wilson’s disease aka progressive hepatolenticular degeneration is an unwonted genetic disorder of copper metabolism. Though its pathogenic inception lies within the hepatobiliary system, the brunt of relentless copper accretion is borne across a multisystemic terrain. The complex symptomatology of this syndrome mandates a high index of suspicion as left undiagnosed it has a tenacious progression with resultant severe disability & death. An accurate & timely diagnosis allows initiation of optimal treatment regimens to prevent or revert its protean manifestations. MRI- based neuroimaging serves to elaborate upon the anatomical, biochemical and pathological correlates of the disease and hence not only facilitates diagnosis and severity assessment but is also instrumental in monitoring therapeutic response. We hereby present the case of a 23 years old female with the neurological, psychiatric, hepatic, and ocular manifestations of Wilson’s disease with relevant radiological correlates. The neuroimaging in this case particularly demonstrates the Face of the giant panda and bisected pons signs in addition to cerebral white matter changes all of which are extremely rarely seen concurrently and hence bequeath exclusivity to our case. In addition, the face of the giant panda sign is an infrequent but pathognomonic feature of Wilson’s disease; and, is also the sole MRI feature that serves to differentiate it from all other early - onset extrapyramidal disorders.

**Keywords:** Copper storage disease, Hepatolenticular degeneration, Wilson disease

---

### I. Introduction

Wilson’s disease is an inborn disorder of hepatocyte copper trafficking caused by impaired function of P-type adenosine triphosphatase (ATPase) encoded by the ATP7B gene.(1) The resultant copper excess initiates toxic damage primarily involving the liver, brain, cornea and kidney.(2) Its phenotypic variability leads to a procrastinated diagnosis, unless buttressed by a high index of suspicion.(1) Among the inborn errors of metabolism, its diagnosis is of paramount significance as it most commonly affects the children and young adults and is a potentially curable disease if recognised and treated early.(1)

From its first scientific account more than a century ago, by Dr. SAK Wilson in 1912, noteworthy inroads have been made pertaining to its awareness, pathogenesis, cellular biology, molecular genetics, fortification of the diagnostic armamentarium and therapeutic breakthroughs with resultant improved prognostication.

### II. Case Report

A 23 years old female patient was referred as a known case of Wilson’s disease (diagnosed 16 months back) with both hepatic (chronic liver parenchymal disease with portal hypertension, ascites and splenomegaly) and neurological involvement. She was subsequently prescribed Zinc and Penicillamine in escalating doses with resultant symptomatic improvement. Now patient had presented with the chief complaints of distension abdomen for the past one month and altered sensorium since the past 3 days.

On clinical examination particular note was made of dystonia, risus sardonicus (Fig.1) & bilateral corneal Kayser-Fleischer rings.

MRI examination of the brain revealed few asymmetric, nonspecific T2 and FLAIR hyperintensities involving the cerebral white matter bilaterally. (Fig.2a) However no area of restricted diffusion was seen & the grey-white matter interface was maintained.

Both intra - and extra-axial fluid spaces were prominent indicative of diffuse cerebral atrophy. (Fig. 2b & c) Bilateral Lentiform nuclei & Thalami displayed extensive & symmetric altered signal intensity areas as hypointense on Axial T1 and hyperintense on T2-weighted & FLAIR images. (Fig. 3b & 4)

The midbrain displayed the characteristic “Face of the Giant Panda” sign on Axial T2-weighted images. (Fig.5a) This is attributable to the tegmental involvement appearing hyperintense, with the relatively preserved red nucleus & lateral portion of the pars reticulata of the substantia nigra appearing hypointense.(3, 4)

The central 2/3rds of the pons appeared hyperintense on Axial T2-weighted images. A hypointense horizontal line was seen interrupting the same with resultant “bisected pons” appearance (Fig. 5b) indicative of central pontine myelinolysis – like changes involving the pontine tissues.(4)

The medulla & cerebellum were unremarkable except for prominent cerebellar folia (Fig.3a) indicative of diffuse cerebellar atrophy.

Sonographic examination of the abdomen revealed a cirrhotic liver with splenomegaly and gross ascites. (Fig. 6a) .These findings were further corroborated on non-contrast CT (Fig.6b) and MRI (Fig.6c & d) sections through the area of interest.

### **III. Discussion**

Wilson’s disease is a rare, familial, autosomal-recessive disorder of copper metabolism, which is characterised by hepatic and neurological manifestations. With the worldwide prevalence rate ranging from 10 to 30 cases per million, increased rates are associated with parental consanguinity .The heterozygote carrier rate is 1 case per 100 persons, corresponding to a gene frequency varying between 0.3% and 0.7%. (5, 6)

Though copper is an essential trace element in the human body, its plethoric aggregates lead to oxidative damage of the hepatocytes with resultant spill over of free copper into the bloodstream. This incites copper overload –induced toxic damage of various organs such as the brain, kidney and cornea. (7)

The molecular pathogenesis is attributable to a mutation in the ATP7B gene on chromosome 13q14.3. This gene (ATP7B) is highly expressed in the liver, kidney, and placenta. It encodes a transmembrane protein ATPase (ATP7B), which functions as a copper-dependent P-type ATPase. The ATP7B transporter has dual synthetic and excretory roles, functioning in the transport of copper into the trans-Golgi compartment, for incorporation into the plasma protein ceruloplasmin, and into the bile, for excretion of excess stores.(1, 8)

Copper transportation capacity of ATP7B mutants is reduced or completely lost with resultant hepatic copper accumulation and subsequent overflow to other organs as brain, kidney and cornea.(1)The age of onset ranges between 5 to 50 years with hepatic sequelae or haemolytic anaemia being the usual rendition in children and neurological manifestations being rare before 10 years of age.(9)

The clinical spectrum encompasses a medley of manifestations including hepatic, neurological, ophthalmic, psychiatric and renal involvement.

Neurological and neuropsychiatric signs are the presenting features in 40–50% of cases and these patients tend to be older than those with hepatic features alone. These abnormalities can be classified as: (a) an Akinetic - rigid syndrome similar to Parkinson’s disease, (b) pseudosclerosis dominated by tremor, (c) ataxia, and (d) a dystonic syndrome. Migraine, insomnia, headache, depression, anxiety, frank psychosis, dysarthria, spasticity and micrographia etc. are additional prevailing correlates.(8)

#### **Neuroimaging Essentials:**

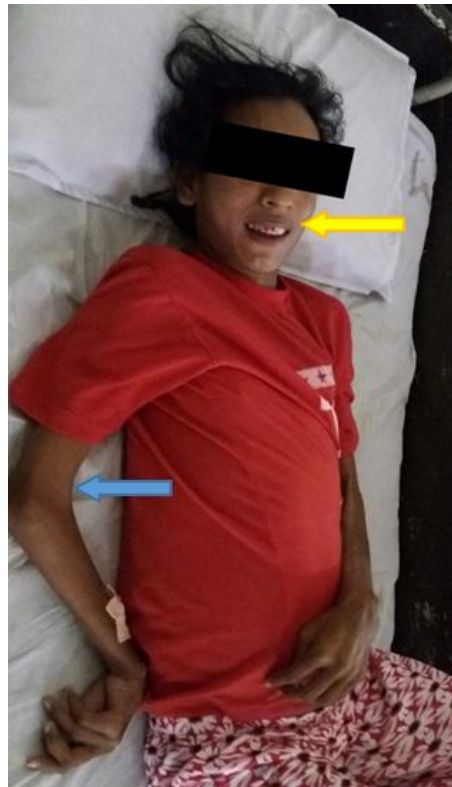Despite the ubiquitous presence of toxic copper within the brain, pathologic findings remain primarily confined to the deep grey matter ( basal ganglia & thalamus ) & subcortical white matter visualised as bilateral symmetrical hyperintensities on T2 –weighted images.(4, 10)

The brainstem though infrequently involved ( preferentially midbrain ) displays MRI signs as Face of the giant panda ( midbrain ), Miniature panda /panda cub ( pons ) and Central pontine myelinolysis-like changes (round shaped lesion/ bisected pons/ trident sign) (3, 4, 11) ; which are considered as defining for the illness.

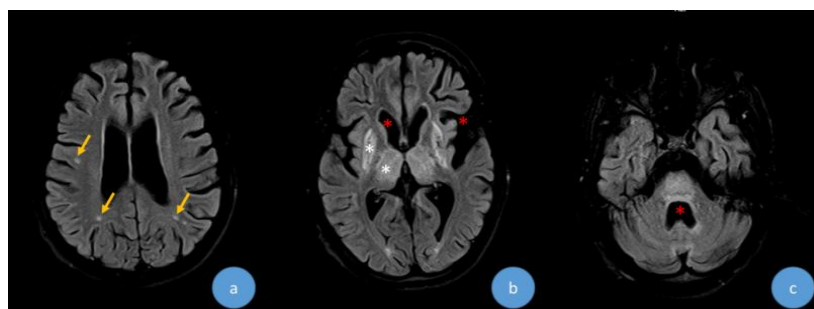The hepatic involvement ranges from fulminant hepatic failure in acute cases to insidious cirrhosis. Hepatocellular carcinoma though a rare association may occur in the setting of cirrhosis and chronic inflammation. (8)

Ophthalmic expression includes corneal Kayser-Fleischer rings (due to granular copper deposition in the Descemet’s membrane at the sclero-corneal junction) and sunflower cataracts (copper deposition in the anterior capsule). 95% of those with neurological and 65% of those presenting with hepatic dysfunction exhibit the KF rings which are the single most crucial clinical diagnostic sign in Wilson’s disease. (12, 13)The knee joint and the spine most commonly exhibit the skeletal component evident as osteomalacia, osteoporosis, spontaneous fractures, adult rickets, osteoarthritis, osteochondritis dissecans, chondrocalcinosis, subchondral cyst formation and the like. Cardiomyopathy and arrhythmias are rare sequelae of myocardial involvement. Hypoparathyroidism, infertility, repeated miscarriages, and renal abnormalities including aminoaciduria and nephrocalcinosis too are quite infrequent. (8)

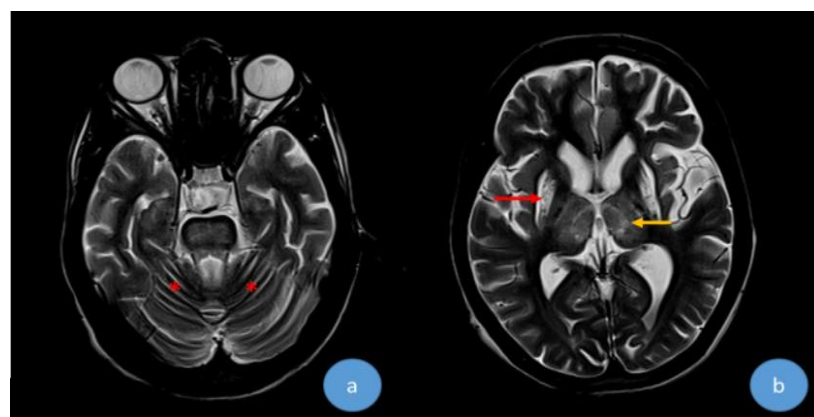
**IV. Figures**



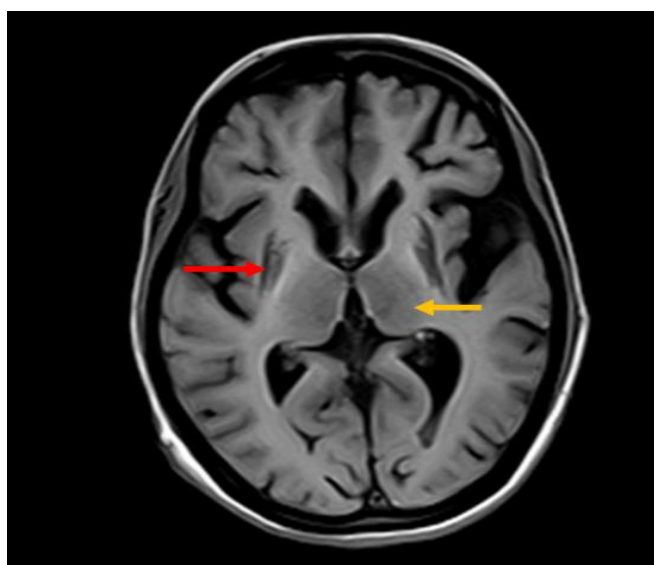
**Fig.1** Clinical Examination reveals (a) Risus Sardonicus (Yellow arrow) (b) Dystonic posture (Blue arrow)



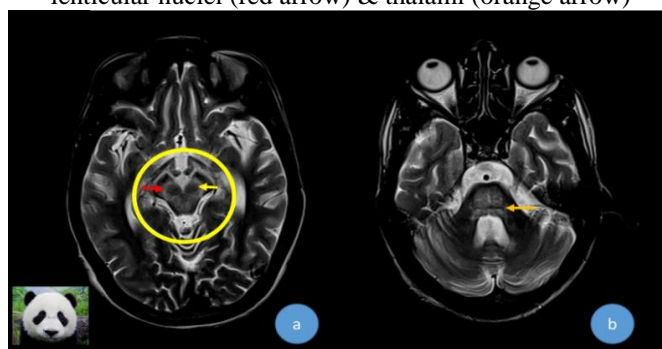
**Fig.2** MRI Axial T2 FLAIR Images reveal (a) Few, bilateral asymmetric, nonspecific white matter hyperintensities in cerebrum (orange arrows) (b) Bilateral symmetric hyperintensities involving basal ganglia (putamina) and thalami (white asterisks) & prominent intra - & extra-axial fluid spaces indicative of cerebral atrophy (red asterisks) (c) Prominent 4<sup>th</sup> ventricle (red asterisk)



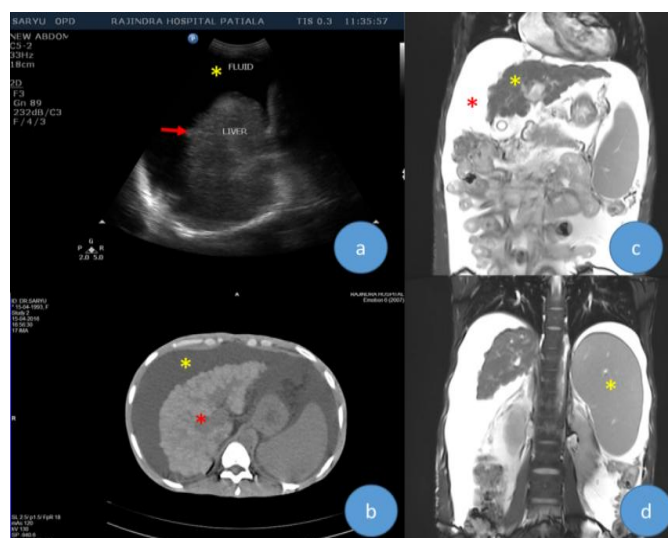
**Fig.3** MRI T2 TSE Axial images reveal (a) Prominent cerebellar folia (red asterisks) (b) BGT lesions: Extensive bilateral symmetric hyperintensities involving lenticular nuclei (red arrow) & thalami (orange arrow)



**Fig.4** MRI T1 Axial images reveal BGT lesions: Extensive bilateral symmetric hypointense areas involving lenticular nuclei (red arrow) & thalami (orange arrow)



**Fig.5** MRI T2 TSE Axial images reveal Brainstem involvement as (a) MIDBRAIN : “Face of the giant panda sign” due to bilaterally preserved signals in red nuclei (yellow arrow) & lateral pars reticulata of substantia nigra with high signal in the tegmentum (red arrow) (b) PONS : “ Bisected Pons” appearance attributed to a hypointense horizontal line (orange arrow) interrupting the hyperintense pontine tissue



**Fig.6** Abdomen evaluation (a) USG reveals cirrhotic nodular liver (red arrow) with gross ascites (yellow asterisk) (b) Non-contrast axial CT image reveals “Honeycomb liver” unique to Wilson disease (red asterisk) & gross ascites (yellow asterisk) (c) MRI T2 TRUF1 COR reveal cirrhotic liver (yellow asterisk) with ascites (red asterisk) with (d) Splenomegaly (yellow asterisk)

## V. Conclusion

Wilson’s disease is not as subtle as was once presupposed and is rather all too frequently misdiagnosed as other more common disorders. Its clinical heterogeneity proves to be the bottle-neck for anticipatory diagnosis even in those with a positive family history & hence delays initiation of treatment. It must be kept in the differentials of any individual with unexplained liver abnormalities or new-onset movement disorders. Though palliative therapeutic regimens viz. orthotopic liver transplantation for fulminant hepatic failure have been formulated which can successfully ameliorate or prevent the otherwise progressive and inevitably fatal course of the disease; it however remains essentially incurable. Novel interventions viz. gene therapy, hepatocyte transplantation are the elixir vitae -in waiting for battling this malady.

### Declarations

- a. Funding Nil
- b. Conflict Of Interest Nil
- c. Ethical approval Not required

### References

- [1]. A. B. Taly LKP, S. Sinha. Wilson’s disease: An Indian perspective. *Neurology India*. 2009;Sept-Oct 57(5):528-40.
- [2]. Wu Q-YDaZ-Y. Advance in the pathogenesis and treatment of Wilson disease; *Translational Neurodegeneration*. 2012; 1(23):1-8.
- [3]. Seiji Hitoshi MI, Kohki Yoshikawa. Mid-brain pathology of Wilson’s disease: MRI analysis of three cases. *Journal of Neurology, Neurosurgery, and Psychiatry*. 1991;54:624-6.
- [4]. Ujjawal Roy AP, Zakir Hussain, Debsadhan Biswas. The entire spectrum of typical and atypical magnetic resonance imaging changes in a single case of Wilson’s disease. *J Neurosci Rural Pract*. 2016;7:321-22.
- [5]. Yue Zhang Z-YW. Wilson’s disease in Asia. *Neurology Asia*. 2011;16(2):103 – 9.
- [6]. Ricardo Schmitt de Bem DAM, Marta Mitiko Deguti, Egberto Reis Barbosa,, Lineu Ce’sar Werneck HIAGT. Wilson’s disease in southern Brazil: a 40-year follow-up study. *CLINICS*. 2011;66(3):411-6.
- [7]. Pfeiffer RF. Wilson’s Disease. *SEMINARS IN NEUROLOGY*. 2007;27(2):123-32.
- [8]. Aftab Ala APW, Keyoumars Ashkan, James S Dooley, Michael L Schilsky. Wilson’s disease. *Lancet*. 2007;369:397-408.
- [9]. SB GROVER PG, A KUMAR, H MAHAJAN. Extensive Gray & White Matter Abnormalities In Wilson’s Disease: A Case Report. *Ind J Radiol Imag*. 2006;16(1):91-4.
- [10]. T.J. Kim IOK, W.S. Kim, J.E. Cheon, S.G. Moon, J.W. Kwon, J.K. Seo, K.M. Yeon. MR Imaging of the Brain in Wilson Disease of Childhood: Findings Before and After Treatment with Clinical Correlation. *AJNR Am J Neuroradiol*. 2006;27:1373-78.
- [11]. Shivakumar R. SVT. Face of the giant panda and her cub. *Neurology*. 2009;72:e50.
- [12]. Subrahmanvaml DSAaDKS. Ocular signs in Wilson disease. *Annals of Indian Academy of Neurology*. 2012;Jul-Sep; 15(3):200–1.
- [13]. Charlotte Anne Sullivan AC, G A Shun-Shin. Dense Kayser-Fleischer ring in asymptomatic Wilson’s disease (hepatolenticular degeneration). *Br J Ophthalmol*. 2002;86:114-23.